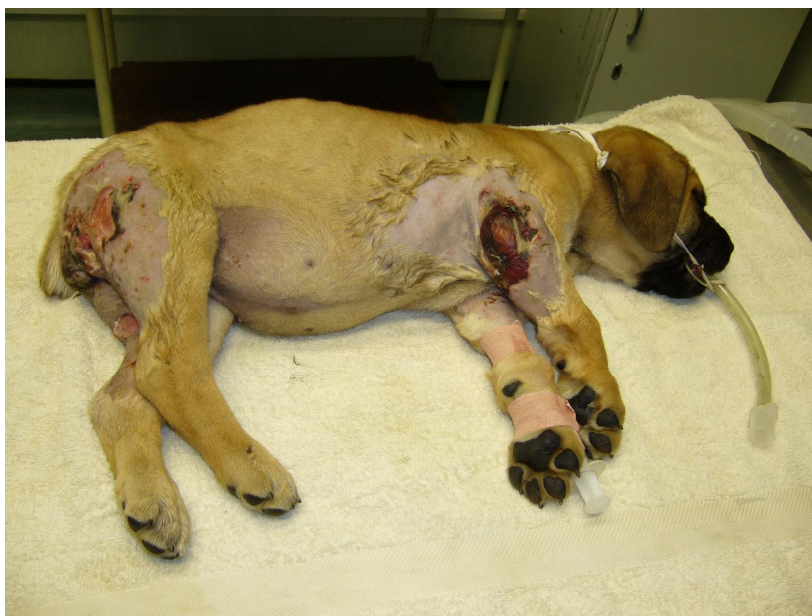

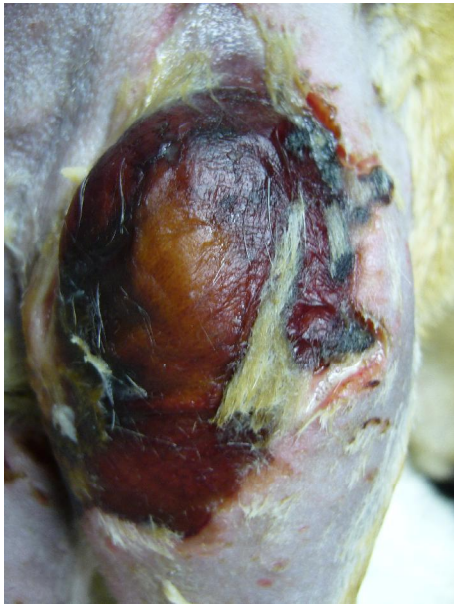Case study: bite wounds

6 week old puppy with necrotic bite wounds

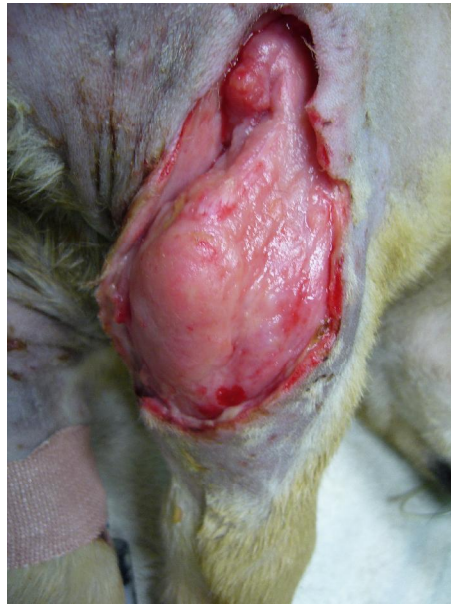- Patient:** 6 weeks old female Boerboel puppy attacked by a Maltese.
- History:** Presented one day after insult, with multiple small puncture wounds on hind limbs and a few on the right front limb, and was treated with antibiotics and anti-inflammatories. Two days later the dog was evaluated again, but now exhibited severe skin necrosis, sloughing of the skin and even of sub-cutaneous tissue as deep as the muscular layers.
- Treatment:** Light therapy was done for 8 minutes, once a day for 5 days, and thereafter once every second day. The patient was kept on concurrent antibiotics, anti-inflammatories and bandage changes and topical dressing, using Intrasite gel, were done every time light therapy was used.
- Outcome:** From the second day of light therapy the wounds started to shallow, no more necrosis took place and granulation tissue started filling the defect. On the hind limbs good wound contraction took place, with minimal scar tissue formation and no further surgery was ever needed in this area. The elbow defect was closed 13 days after surgical debridement. Overall what seemed as an impossible extent of tissue damage healed much faster than initially predicted. Due to the shortened time period to recovery, less bandages were used than initially expected, saving on costs and the puppy was back to being a puppy in no time.



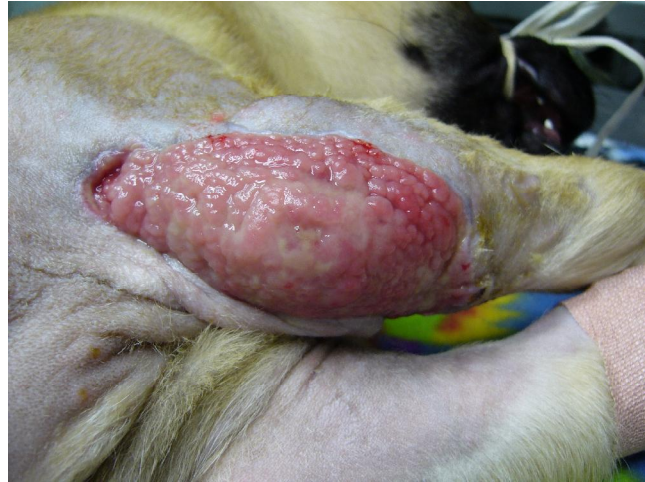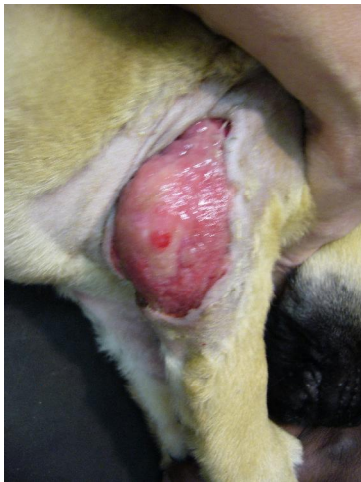Presenting patient, 3 days after being attacked by a Maltese



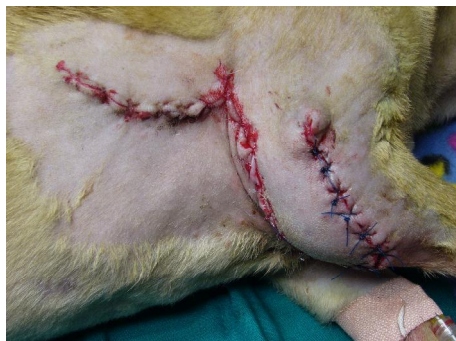**Presenting right elbow
Severe necrosis of skin**



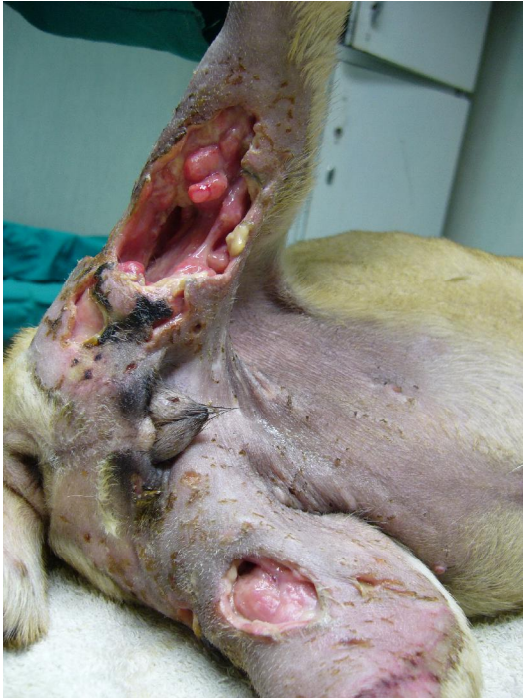
**Elbow after surgical debridement
Light therapy started thereafter**



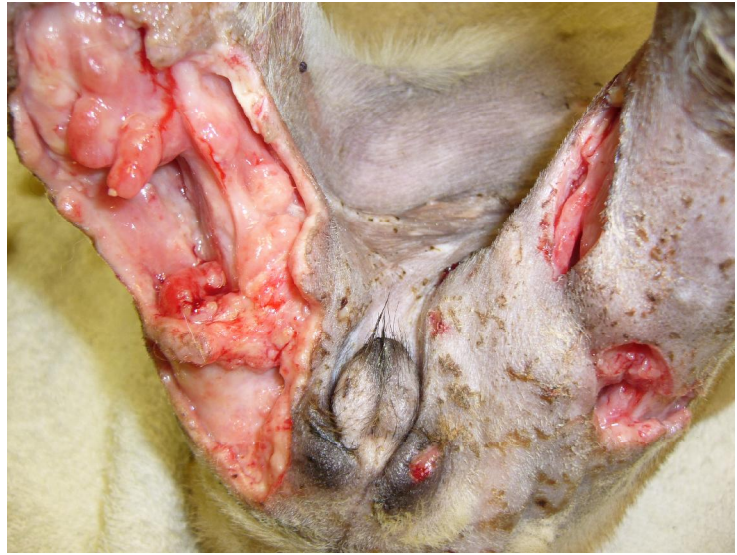8 Light therapy sessions and 12 days later, good granulation tissue formation



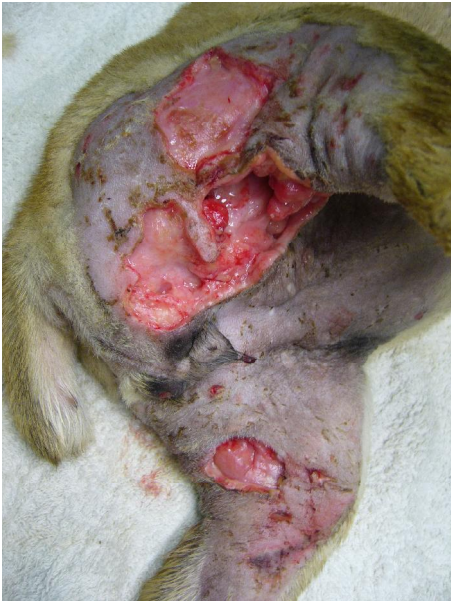Skin flap: 13 days after the start of light therapy



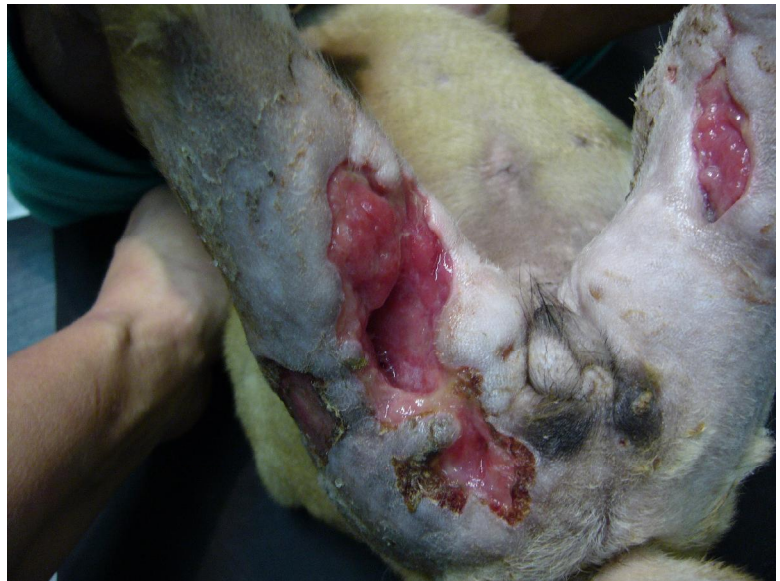Presenting wounds on hind limbs



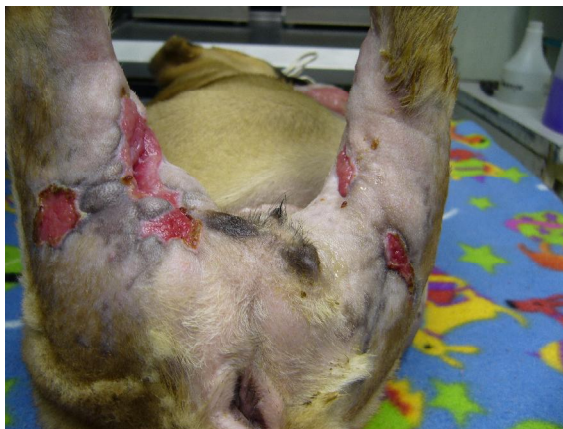Wounds on hind limbs after surgical debridement



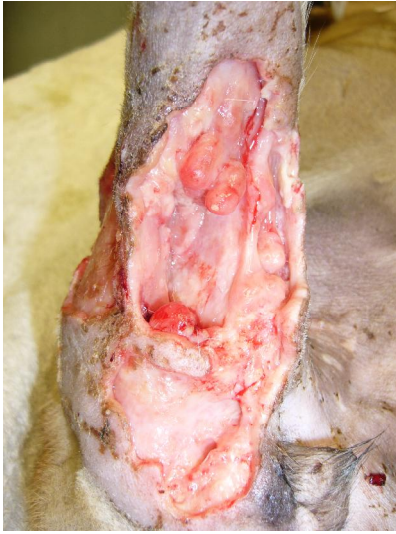Wounds after debridement



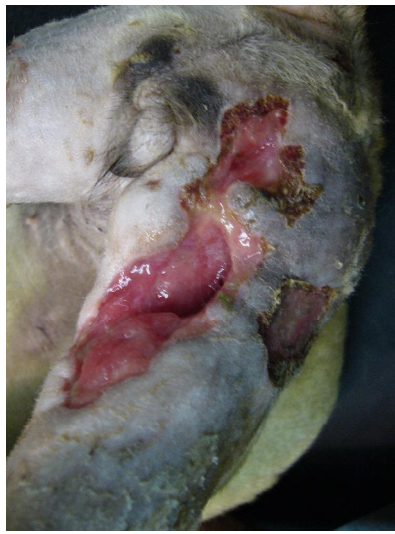7 Light therapy sessions and 10 days later



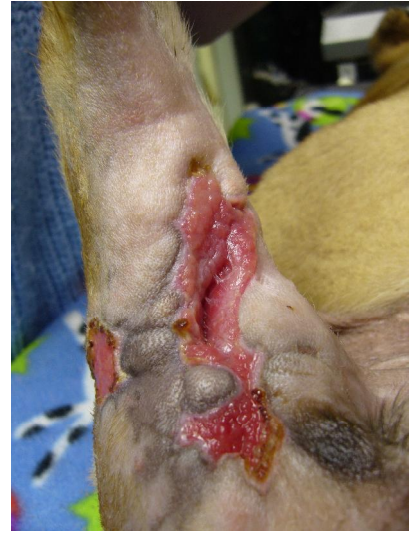**8 Light therapy sessions and 12 days later
Good contraction of the wounds, no surgery was needed**



Wounds after debridement



**7 Light therapy sessions
and 10 days later**



**8 Light therapy sessions
and 12 days later**

Good contraction of the wounds, no surgery was needed