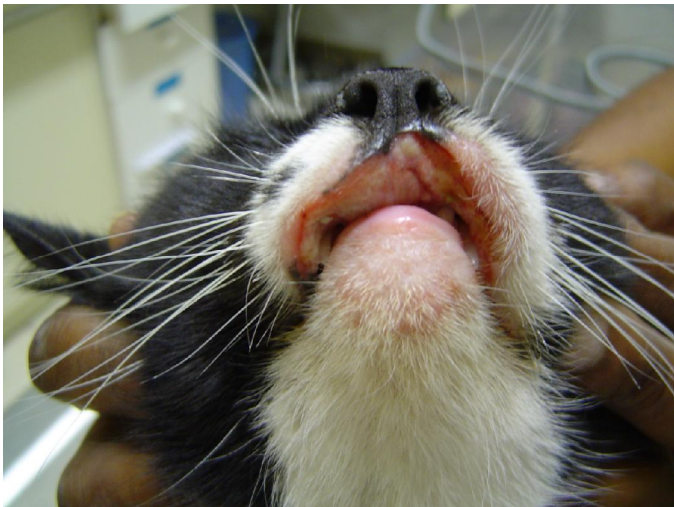


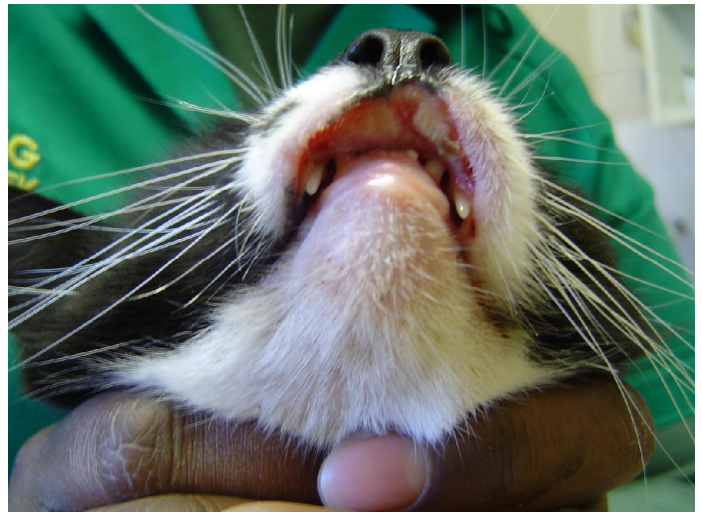Case study:

Eosinophilic ulcer on the lip

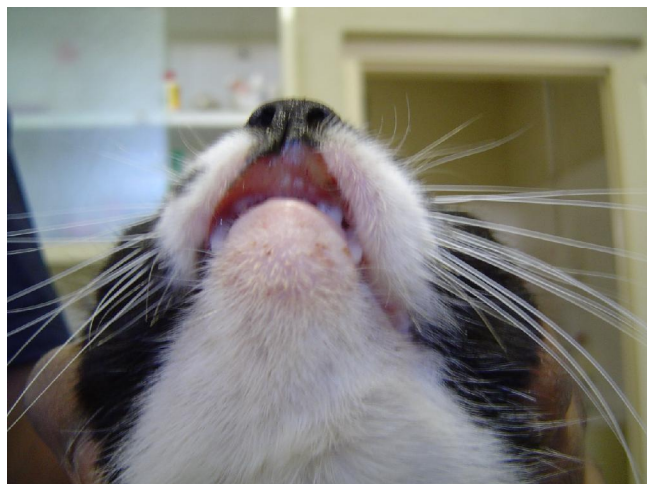
- Patient:** 5 year old female cat with recurrent eosinophilic ulcer on the upper lip.
- History:** Previously treated with depo-medrol injections and antibiotics. Due to the side-effects of cortisone an alternative treatment modality was requested, and so light therapy was given as sole treatment.
- Treatment:** Light therapy was done for 5 minutes, once a day, for 5 days and thereafter once a day, 3 times a week, for 5 days. The wound took, in total, 16 days to heal completely. No other medication was given.
- Outcome:** From the second day of light therapy the lip was much less swollen, with less necrosis and healthy tissue could fill the defect. As expected, the lesion re-occurred a month later and light therapy was started again. The lesion regressed again (full results still pending).
- Conclusion:** Light therapy can be used as sole or as adjunct therapy for “rodent ulcer” lesions but will not cure the disease complex indefinitely.



Presenting lesion
Severe swelling and necrosis present



2 sessions of light therapy later
Less necrotic tissue and swelling



After 5 sessions of light therapy
Dramatic improvement with minimal swelling